

Early Morphofunctional Response of Contact Tissue after Intraosal Implantation in Rabbit Jaw of Pure Synthetic Hydroxyapatite (HAp) Bioceramic Materials and HAp Saturated with Lidocaine

Ilze Salma, Mara Pilmane, Andrejs Skagers, Janis Vetra, Girts Salms, Liga Berzina-Cimdina, Rita Serzane

SUMMARY

Purpose. The aim of this study was to evaluate early morphofunctional response of contact tissue to pure and saturated with lidocaine porous synthetic HAp ceramic implants inserted in holes of rabbit upper jaw.

Materials and Methods. Pure and saturated with lidocaine cylinders of porous HAp ceramics produced at Biomaterials R&D Laboratory of Riga Technical University were inserted into edentulous part of the upper jaw of 12 New Zealand male rabbits. After two weeks, blocks of soft tissue and bone were taken out. The sections done with EXACT Grunding system and from paraffin blocks were stained with haematoxylin/eosin and by use of biotin-streptavidin immunohistochemistry for transforming growth factor β 1 (TGF β 1), fibroblast growth factor receptor 1 (FGFR1), interleukin 10 (IL10). Apoptosis was detected by TUNEL method.

Results. TGF β 1 was equally expressed in the bone around HAp implants saturated with lidocaine and without lidocaine, while control sections did not show any expression of TGF β . In contacting bone tissue to pure HAp and HAp saturated with lidocaine as well in controls rich expression of FGFR1 was observed. In soft tissue of experimental samples also rich expression of FGFR1 was observed, although it was weak in control samples. IL10 had rich expression in all samples. The mean number of apoptotic cells was higher in samples with pure HAp, slightly decreased in samples HAp with lidocaine and significantly lower in controls.

Conclusions. The expression of TGF β 1 confirms osteoinductive activity of HAp. Contact soft tissue to HAp showed rich FGFR1 expression, and weak in controls suggesting higher plasticity of connective tissue to implants in comparison with supportive tissue.

Slightly lower apoptosis in samples of HAp with lidocaine gives evidence of indistinct influence of saturated with lidocaine HAp implants on development of programmed cell death.

Key words: implantation of hydroxyapatite in bone, lidocaine, transforming growth factor β , fibroblast growth factor receptor, interleukin 10, apoptosis.

INTRODUCTION

Augmentation of various congenital and acquired defects of bone tissue is a topical problem in oral

and maxillofacial surgery. Around half of the patients requiring dental implants has severe alveolar

¹Department of Oral and Maxillofacial Surgery, Riga Stradins University

²Institute of Anatomy and Anthropology, Riga Stradins University

³Center for Development and Innovation of Biomaterials, Riga Technical University

*Ilze Salma*¹ – MD, Mg (Biomaterials and Biomechanics), PhD student

*Mara Pilmane*² – MD, Dr. hab. med, professor, Director of Institute of Anatomy and Anthropology

*Andrejs Skagers*¹ – MD, Dr. hab. med, professor, Head of Department of Oral and Maxillofacial Surgery

*Janis Vetra*² – MD, Dr. hab. med., professor

*Girts Salms*¹ – MD, DDS, MRCSEd, Mg (Biomaterials and Biomechanics), lecturer

*Liga Berzina-Cimdina*³ – DrIng, Asoc.professor, Head Center for Development and Innovations of Biomaterials

*Rita Serzane*³ – PhD student, Faculty of Material Science and Applied Chemistry

Address correspondence to Ilze Salma, Riga Stradins University, Department of Oral and Maxillofacial Surgery, Dzirciema str. 20, Riga LV 1007, Latvia.

E-mail: salma.ilze@gmail.com




Fig. 1. Light microscopy of HAp ceramic surface




Fig. 2. Scanning electron microscopy of HAp ceramic

bone deficit which can be replaced using bone grafting from the patient, biomaterials or combination of both. Autografts usually imply additional operation with donor site morbidity and unpredictable graft resorption in a long term. The aim of reconstruction of soft and hard tissues is to achieve optimal functional stability and good aesthetic result [1].

Early stages in osseointegration of bone substitutes run in a close interaction of inflammatory and regenerative processes. Biomaterials of different origins as natural and synthetic ones have different mechanisms of host response. Biomaterials should be stable, biocompatible, ideally osseointegrative and conductive, porous and similar to biological bone mechanically [2]. Synthetic HAp is artificially created main mineral constituent of bone and as such it has no biological ingredients possible to initiate immunological response. Calcium phosphate ceramics and bioactive glass started to be used for bone substitution 30 years ago. These materials are considered bioactive because they join with bone and enhance bone regeneration [2].

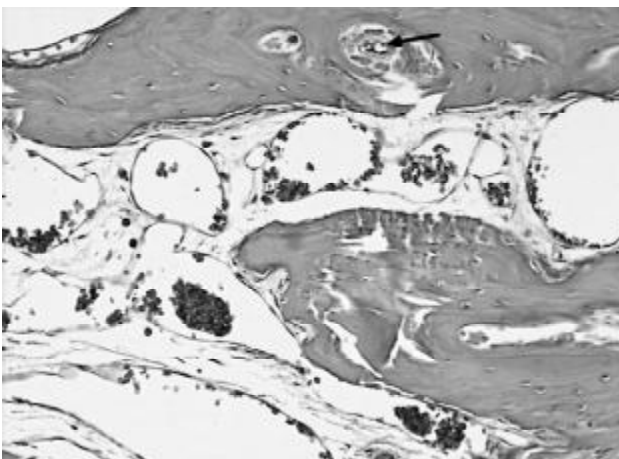


Fig. 3. Bone and connective tissue around pure HAp implant inside jaw bone. Haem/ eos, x200.

Besides the main aim of bioceramic as bone substitutes seeding of biomaterials with drugs in order to diminish inflammatory response may be important for improvement of postoperative care and decrease a need of anti-inflammatory and analgesic drugs. The local use of drugs may reduce dosage and side effects and provide higher concentration in the area of surgical intervention [3].

HAp saturated with local anaesthetic lidocaine may diminish pain and inflammation in the early postoperative period.

The objective of this study was evaluation of early morphofunctional response of contact tissue to pure and saturated with lidocaine porous synthetic HAp ceramic implants inserted in holes of rabbit upper jaw.

MATERIALS AND METHODS

Preparation of implants

Porous hydroxyapatite (HAp) ceramics were obtained from HAp powder synthesized at

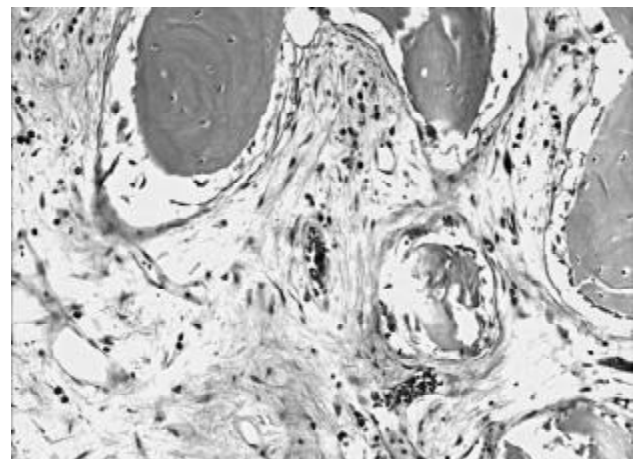


Fig. 4. More connective tissue around HAp implant saturated with lidocaine. Haem/eos, x200.

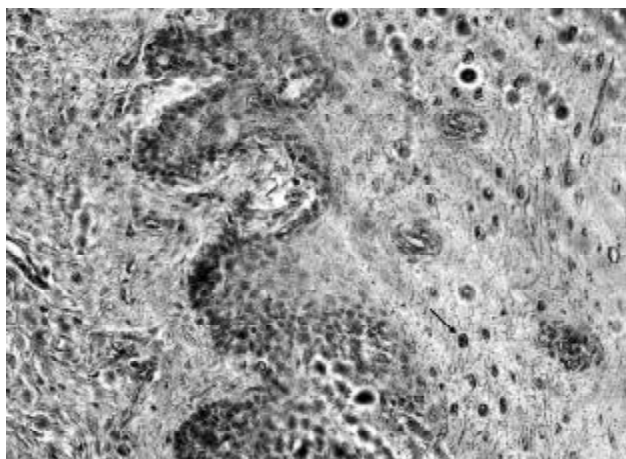


Fig. 5. Rich expression of FGFR1 in connective tissue after HAp implantation. IMH, FGFR1, x200.

Biomaterials R&D Laboratory of Riga Technical University using wet chemical method from $\text{Ca}(\text{OH})_2$ and H_3PO_4 solutions and calcinated at 800 °C. To form green bodies, HAp powder was mixed with paraffin wax and gelatin (70:25:5) and uniaxially pressed in a form of a cylinder (1.8 mm diameter, 4 mm length). The green bodies were sintered at 1100°C. The porosity of obtained ceramics was 25-30%, water uptake 10-13% from mass and volume mass 2.1-2.2 g/cm³ (Figures 1, 2).

Synthetic HAp ceramic cylinders were saturated with Sol. Lidocaini hydrochloridi 2% using vacuum extraction method. Every HAp ceramic cylinder contains 1.6 mg of Lidocaini hydrochloridi.

Implantation of HAp cylinders in rabbit upper jaw

With permission of the Animal Ethics Committee of Latvian Food and Veterinary Administration experimental operations on 14 New Zealand male rabbits (weight 3.5 kg) were done (Table). Local anaesthesia with Sol. Lidocaini 2% (4 mg/kg) as well general anaesthesia with Ketamin 15 mg/kg and Midazolam 0.5 mg/kg was performed.

After rising of mucoperiosteal flap in edentulous part of the right upper jaw a hole of 2.0 mm diameter was drilled, HAp cylinder of 1.8 mm diameter with lidocaine or without lidocaine was inserted and the wound was closed in two layers. On the left side the same operation without insertion of HAp implants was done.

Table. Design of experiment

Implant type and site	No of animals
Intraoral implantation of pure HAp ceramic in upper jaw	6 rabbits
Intraoral implantation of HAp ceramic with lidocaine in upper jaw	6 rabbits
Control – identical operation, without HAp ceramic implantation	2 rabbits

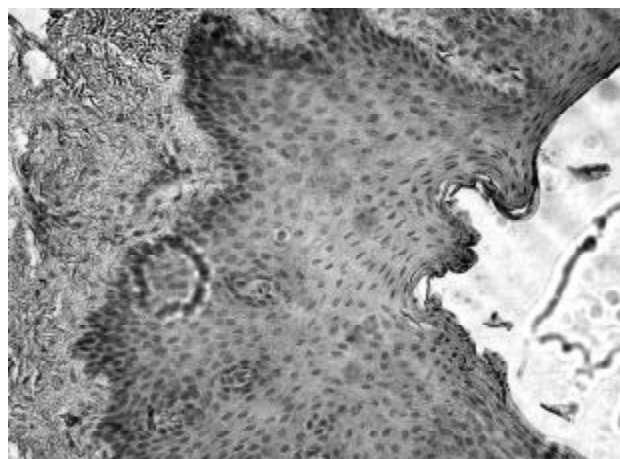


Fig. 6. Expression of FGFR1 in control tissue. IMH, FGFR1, x200.

Histological and immunohistochemical evaluation

After two weeks euthanasia by air embolisation was performed. The blocks of soft tissue and bone were taken out, and fixed in Stefanini solution. Sections done with EXACT Grinding system and from paraffin blocks were stained with haematoxylin/eosin for review of the picture and using biotin and streptavidin immunohistochemical methods [Hsu et al., 1981]. The samples of bone and contacting soft tissue were prepared and evaluated regarding expression of transforming growth factor β 1 (TGF β 1, 1279, 1:1000, Cambridge Science Park, UK) and fibroblast growth factor receptor 1 (FGFR1, 10646, 1:100, Cambridge Science Park, UK). Evaluation of interleukin 10 (IL10, code ab34843, 1:400, Abcam, UK) was also performed in soft tissue. TUNEL method was used for evaluation of apoptosis in contacting soft tissue [5]. Results were analyzed using semiquantitative analysis [6].

RESULTS

Histology

On histological slices stained with haematoxylin/eosin in gingival tissue around pure HAp ceramic implants a capsule of connective tissue and degenerative epitheliocytes without inflammation have formed. Analyzing bone tissues after pure HAp implantation, we observed uneven bone trabeculas with few osteones and soft tissues have ingrown in bone channels (Figure 3). After implantation of HAp with lidocaine we found massive proliferation of connective tissue between bone fragments (Figure 4).

Immunohistochemistry

In bone tissue there was rich expression of FGFR1 in experimental side (HAp and HAp with

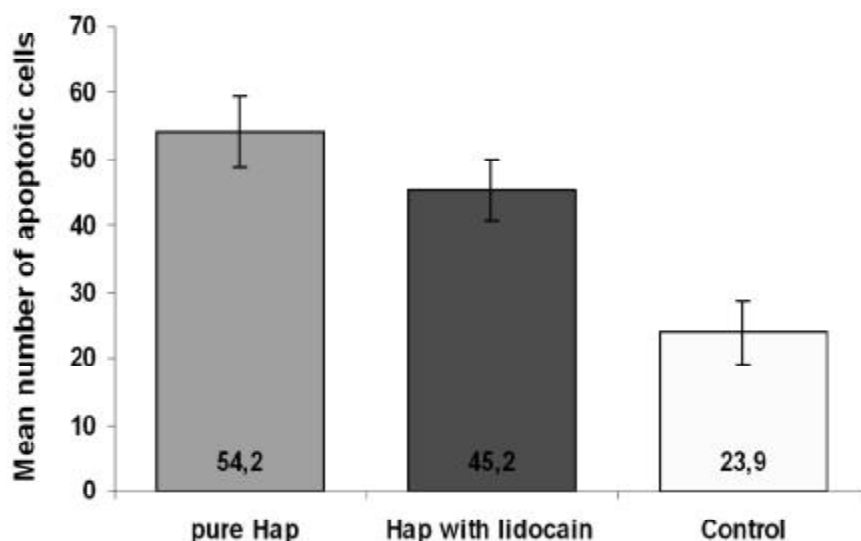


Fig. 7. Comparison of mean number of apoptotic cells in contact tissue after different biomaterial implantation and control

lidocaine) and in control side. TGF β was intensively expressed in cells of endosteum and bone around pure HAp implants, but it had moderate expression in bone and intensive expression in endosteum with HAp with lidocaine. On the control side only endosteum was TGF β positive, while osteocytes were factor negative.

Connective tissue structures possess rich FGFR1 expression around HAp implants with lidocaine and without lidocaine (Figure 5), while control tissue demonstrated only few cells positive for FGFR1 (Figure 6).

Apoptosis

The mean number of apoptotic cells was higher after pure HAp ceramic implantation – 54.2 in comparison with HAp ceramic with lidocaine – 45.2, but in control tissue the mean value of apoptotic cells was 23.9 (Figure 7).

DISCUSSION

In our experiment, the contact soft tissue response to implantation of pure HAp and HAp cylinders with lidocaine regarding the type and activity of inflammation was similar with normal wound healing of the same bone in the same part. A thin capsule of connective tissue appeared around HAp ceramic without signs of inflammation. Inflammation and foreign body reaction are common threads in all implanted synthetic materials. Optimum soft-tissue biocompatibility, characterized either by thin fibrous encapsulation or by mesenchymal ingrowth into pores, is achieved by avoiding the body's natural response to an implanted foreign body [7]. Non-specific reactogenicity which becomes apparent

mainly through influence on inflammation and its after effects usually on histological level has compared with morphology of wound healing of the same tissue in the same topographic anatomy relations as on operation with implant insertion [8]. Rucker [9] reports results after synthetic hydroxyapatite implantations into the dorsal skin fold chamber of mice. After 14 day period implantation of HAp causes slight increase in leukocyte recruitment compared with the control. In our experiment the lack of remarkable inflammation was also confirmed by moderate expression of IL10,

cells immunohistochemical marker of inflammation that did not differ from the control group.

TGF β 1 was expressed at higher levels during chondrogenesis and osteogenesis during normal fracture healing of the rat femur [10]. Langdahl [11] reported that TGF β 1 is produced by osteoblasts and it inhibits osteoclast proliferation and activity and stimulates proliferation and differentiation of preosteoblasts. Data from numerous *in vitro* experiments have demonstrated conflicting results regarding the role of TGF β 1 in bone formation. Most data support the opinion that TGF β 1 stimulates the proliferation of osteoblasts, as well promotes the early stages of differentiation and bone matrix production. On the other hand, it blocks later phases of differentiation and mineralization [12]. *In vivo* situation, in which osteoblasts are found in tight clusters, corresponds best to a confluent culture; TGF β 1 stimulates osteoblast proliferation [13]. *In vivo*, the presence of other growth factors in the bone environment and environment as such determine the exact outcome of TGF β 1 functioning. In our results positive expression of TGF β 1 in contact bone tissue may confirm osteoinductive activity of HAp.

Hughes and Hall [14] reported that FGF-1 and FGF-2 are widely expressed in normal adult tissue, as well as FGFR-1, FGFR-2 and FGFR-3. FGF-1 and FGF-2 and their receptors have been implicated in a wide range of normal physiological processes *in vivo* and in various disease states, including certain forms of neoplasia and neurodegenerative disorders [14]. The interpretation of FGF expression is consistent with the multifunctional nature of FGF ligands that induce

diverse cellular responses in multiple cell types as proliferation, differentiation, chemo taxis. Variations in FGFR expression may in turn lead to functional differences essential for the coordinate regulation of tissue homeostasis and complex processes, such as wound healing and tissue repair, that involve more than one cell type and demand biological responses from individual cells [15]. Szebenyi [16] mentioned that FGF stimulates the migration and regeneration of endothelial cells, is promoter of angiogenesis and stimulates wound healing. Our findings prove the above mentioned role of FGFs in regenerative mechanisms of tissues. The intensive expression of FGFR1 in soft tissues around the HAp implants indicates stimulation of adaptive/compensatory mechanisms of regeneration in connective tissue.

Inayat-Hussain [17] confirms that the HAp compounds are not cytotoxic where the mode of death was primarily *via* apoptosis. Several studies demonstrate that cell apoptosis is related to the size of the HAp particles [18], as well of HAp/TCP (hydroxyapatite/tricalcium phosphate) ratio in biphasic ceramic [19]. These results, namely, that implantation of HAp with lidocaine initiates slightly less apoptosis as pure HAp are interesting while the effect of lidocaine on cells is conflicting. Werdenhausen [20] reported that lidocaine triggers apoptosis, although the underlying mechanisms

still remain unknown. Lei [21] investigated neuronal apoptosis and found that infusion of lidocaine diminished DNA fragmentation in the penumbra and the infarct-reducing effects of lidocaine may be due, in part, to the inhibition of apoptotic cell death.

CONCLUSIONS

Within the limits of our study, the following conclusions can be drawn:

1. The expression of TGF β 1 confirms osteoinductive activity of HAp.
2. Contact soft tissue to HAp showed rich FGFR1 expression, but weak in controls suggesting higher plasticity of the connective tissue to implants in comparison with the supportive tissue.
3. Slightly less apoptosis in samples of HAp with lidocaine gives evidence of the indistinct influence of saturated with lidocaine HAp implants on development of programmed cell death.

ACKNOWLEDGEMENTS

This work was supported by Grant No 04.1224 from the Latvian Council of Science and project "Perspective Biomaterials and Medical Technologies" from the Latvian Ministry for Education and Science.

REFERENCES

1. Rehear GM, Meijer GJ, Smelled LE. Reconstruction of defects in the oral and maxillofacial region. A review of the various options for treatment. *Ned Tijdschr Tandheelkd* 2007; 114(1): 47-53.
2. El-Ghannam A. Bone reconstruction: from bioceramics to tissue engineering. Expert review of medical devices 2005; 2(1):87-101.
3. Hunt JA, Williams DF. Modification of the soft tissue response to implanted materials through use of an anti-inflammatory drug. *J Mater Sci* 1992; 3:160-169.
4. Ruhe P.Q, Boerman O.C, Russel F.G, Mikos A.G, Spauwen P.H, Jansen J.A. In vivo release of rhBMP-2 loaded porous calcium phosphate cement pre-treated with albumin. *J Mater Sci Mater Med* 2006; 10:919-27.
5. Negoescu A, Guillermet C, Lorimier P, Brambilla E, Labat-Moleur F. Importance of DNA fragmentation in apoptosis with regard to TUNEL specificity. *Biomed Pharmacother* 1998; 52(6):252-8.
6. Pilmane M, Rumba I, Sundler F, Luts A. Patterns of distribution and occurrence of neuroendocrine elements in lungs of humans with chronic lung diseases. *Proc. of the Latvian Academy of Sciences, Section B*, 1998; 53:144-152.
7. Morehead JM, Holt GR. Soft tissue response to synthetic biomaterials. *Otolaryngol Clin North Am* 1994 Feb; 27(1):195-201.
8. Williams DF. On the mechanisms of biocompatibility. *Biomaterials* 2008; 29:2941-2953.
9. Rucker M, Laschke MW, Junker D, Carvalho C, Tavassol F, Mülhaupt R, Gellrich NC, Menger MD. Vascularisation and biocompatibility of scaffolds consisting of different calcium phosphate compounds. *J Biomed Mater Res A* 2008; 86(4): 1002-11.
10. Joyce ME, Roberts AB, Sporn MB, Bolander ME. Transforming growth factor-beta and the initiation of chondrogenesis and osteogenesis in the rat femur. *J Cell Biol* 1990; 110(6):2195-207.
11. Langdahl BL, Carstens M, Stenkjaer L, Eriksen EF. Polymorphisms in the transforming growth factor beta 1 gene and osteoporosis. *Bone*. 2003 Mar;32(3):297-310.
12. Maeda S, Hayashi M, Komiya S, Imamura T, Miyazono K. Endogenous TGF-beta signaling suppresses maturation of osteoblastic mesenchymal cells. *EMBO J* 2004; 23(3): 552-63.
13. Janssens K, ten Dijke P, Janssens S, Van Hul W. Transforming growth factor β 1 to the bone. *Endocrine Rev* 2005; 26:743 - 774.
14. Hughes SE, Hall PA. Immunolocalization of fibroblast growth factor receptor 1 and its ligands in human tissues. *Lab Invest* 1993; 69(2):173-82.
15. Hughes SE. Differential expression of the fibroblast growth factor receptor (FGFR) multigene family in normal human adult tissues. *J Histochem Cytochem* 1997; 45(7):1005-19.
16. Szebenyi G, Fallon JF. Fibroblast growth factors as multifunctional signalling factors. *Int Rev Cytol* 1999; 185:45-106.
17. Inayat-Hussain SH, Rajab NF, Roslie H, Hussin AA, Ali AM, Anuar BO. Cell death induced by hydroxyapatite on L929 fibroblast cells. *Med J Malaysia* 2004; 59:176-7.
18. Shi Z, Huang X, Cai Y, Tang R, Yang D. Size effect of hydroxyapatite nanoparticles on proliferation and apoptosis of

- osteoblast-like cells. *Acta Biomater* 2009; 5(1):338-45.
19. Lu J, Blary MC, Vavasseur S, Descamps M, Anselme K, Hardouin P. Relationship between bioceramics sintering and micro-particles-induced cellular damages. *J Mater Sci Mater Med* 2004; 15(4): 361-5.
 20. Werdenhausen R, Braun S, Essman F, Schulze-Osthoff K, Walczak H, Lipfert P, Stevens MF. Lidocaine induces apoptosis via the mitochondrial pathway independently of death receptor signaling. *Anesthesiology* 2007; 107(1):136-43.
 21. Lei B, Popp S, Capuano-Waters C, Cottrell JE, Kass IS. Lidocaine attenuates apoptosis in the ischemic penumbra and reduces infarct size after transient focal cerebral ischemia in rats. *Neuroscience* 2004; 125(3):691-701.

Received: 09 03 2009
Accepted for publishing: 28 12 2009